Boonthai and Losty
Annals of Pediatric Surgery (2023) 19:30
https://doi.org/10.1186/s43159-023-00262-y

Annals of Pediatric Surgery

CASE REPORTS

Open Access

Utility of the Kimura technique for the definitive management of high jejunal atresia

Ampaipan Boonthai[1*] and Paul D. Losty[2]

Abstract

Background Operative management of high jejunal atresia may be challenging due to significant size discrepancy between the dilated proximal jejunum and distal atretic bowel.

Case presentation We report a female newborn infant with a high type 1 proximal jejunal atresia located precariously at the duodenojejunal flexure which was successfully corrected with the Kimura operation, i.e., jejunojejunostomy as originally first described for duodenal atresia. The patient was weaned onto full enteral feeds by the end of the first postoperative week and promptly discharged without complication(s).

Conclusions The utility and versatility of Kimura's diamond-shaped anastomosis are highlighted in this unique case report.

Keywords Jejunal atresia, Kimura technique, Diamond-shaped anastomosis

Background

Jejunoileal atresia (JIA) is reported in 0.9 in 10,000 live births and is a notably common cause of neonatal intestinal obstruction [1]. Operative management of JIA is based on operative pathologic findings and specific circumstances. Simple atresia(s) can be successfully managed by intestinal anastomosis with or without bowel resection but in some cases where massive intestinal luminal size discrepancy exists additional procedures such as intestinal tapering, plication, or enteroplasty may be required to achieve good outcome(s) [2, 3].

Anatomically high proximal atresia lesions may pose special challenges compared to those located in the distal intestinal tract making the correction with primary anastomosis complex. High jejunal atresia often refers to an atresia located in the proximal small intestine less than 30 cm distal to the ligament of Trietz where a marked discrepancy between the diameter of the proximal and distal jejunum can be significant and potentially cause major anastomotic complications [4]. As the atretic segment may be crucially located at the DJ flexure variant complex anatomy together with the vascular watershed at the fourth part of the duodenum (D4) makes any effort at mobilization here hazardous and/or bowel resection for corrective anastomosis almost impossible.

Faced with these specific challenges with a newborn infant we successfully deployed the Kimura operation in definitive primary corrective of a DJ flexure high jejunal atresia. Of particular note in this index case no additional plication or intestinal resection operations were required.

Case presentation

A term female newborn infant with a birth weight of 3.2 kg and prenatal diagnosis of jejunal atresia was delivered by elective C-section due to previous maternal obstetrical history (Fig. 1). A post-natal abdominal x-ray film (AXR)

*Correspondence:
Ampaipan Boonthai
ampaipan.nam@mahidol.edu
[1] Division of Pediatric Surgery, Faculty of Medicine, Ramathibodi Hospital, 270 Rama6 Road Phayathai Ratchathevi, Bangkok 10400, Thailand
[2] Institute Of Systems Molecular And Integrative Biology, University of Liverpool, Liverpool, UK

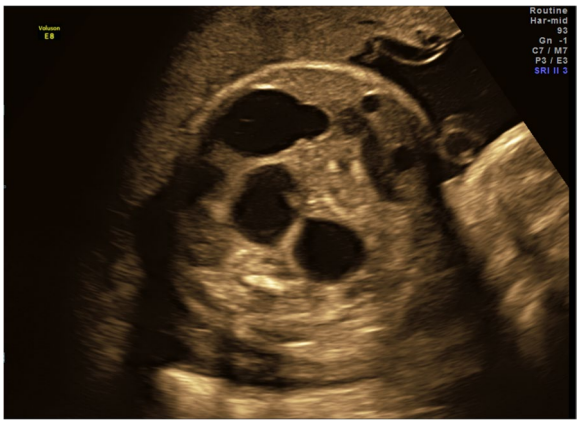

Fig. 1 Prenatal ultrasound image. Prenatal ultrasound image showing a "triple-bubble sign" in a 30-week fetus with mild maternal polyhydramnios

showed gross dilatation of proximal intestinal bowel loops with absent distal gas highly suspicious of proximal jejunal atresia (Fig. 2). There were no other co-associated anomalies detected.

An orogastric tube yielded 30 ml of dark bile content. After IV fluid resuscitation and newborn stabilization, an operation was scheduled on the 2nd day of life.

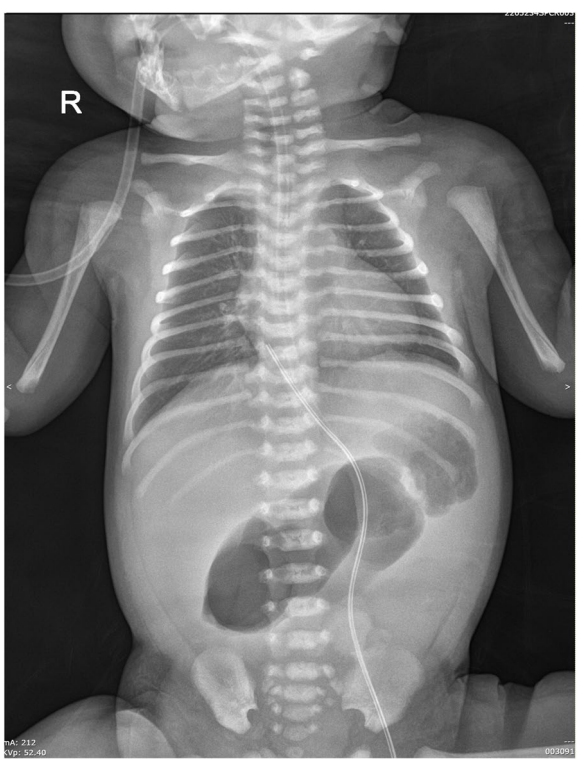

Fig. 2 Postnatal x-ray film (AXR). Postnatal x-ray film showing gross dilatation of the proximal bowel with an absent distal gas pattern — "triple-bubble sign"

Intraoperative findings showed a proximal high type 1 jejunal atresia located critically at the DJ flexure with some 4:1 disproportionate discrepancy (Fig. 3).

Operative technique

We undertook a very limited delicate mobilization of the proximal 4th part of the duodenum creating a transverse incision at this point where a membrane luminal obstruction was identified. Bile together with air bubbles were noted in the gut lumen which confirmed patency of the upstream proximal duodenum. Noting the appreciable size discrepancy and very high location of the gut atresia which would make further mobilization hazardous, we undertook a longitudinal incision in the distal proximal jejunum (Fig. 4) to construct a Kimura jejunojejunostomy primary anastomosis. The anastomosis was successfully completed using interrupted serial 5-0 PDS sutures. No other distal intestinal atresia lesions were evident.

Post-operative aftercare and follow-up

The infant made a rapid uneventful postoperative recovery. Total parenteral nutrition (TPN) was prescribed in anticipation of significant bowel dysmotility and delayed enteral feeding. We initiated enteral feeding on day 7 post-operatively. Time to then achieve full-enteral feeding was 7 days with a total hospital stay of 24 days. At hospital clinic visits 1 and 3 months after discharge the baby was thriving with body weight (BW) and head

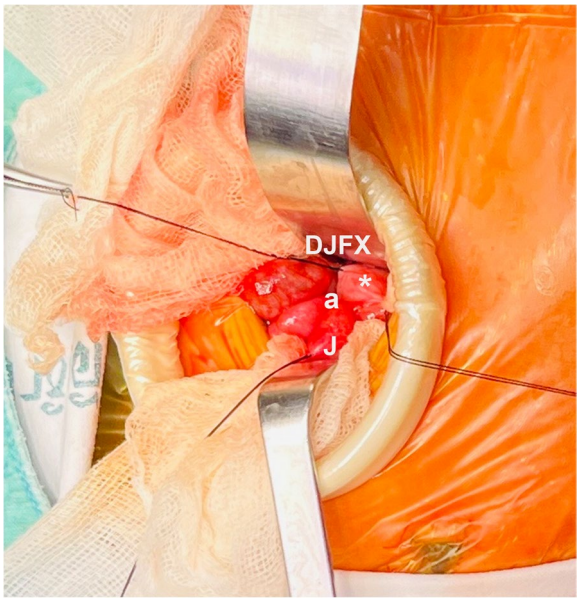

Fig. 3 Intraoperative photograph. Intraoperative photograph demonstrating a high type 1 jejunal atresia. Stay sutures are anchored at the proximal jejunum (*) just immediately below the duodenojejunal flexure (DJFX). Distal jejunum (J) is highlighted below the atretic site (**a**)

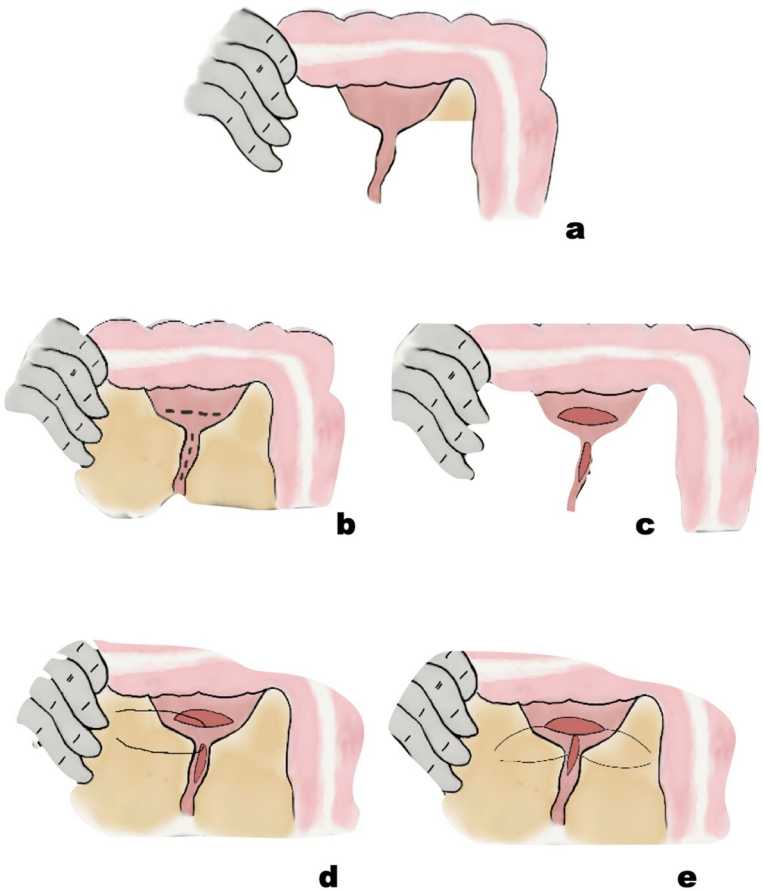

Fig. 4 Illustration of the operative procedure. **a** Significant size discrepancy between the proximal and distal bowel segments just below the DJ flexure (DJFX). **b**, **c** Creation of a transverse incision in the dilated obstructed proximal bowel with a longitudinal incision placed in the adjacent site distal jejunum to create a Kimura primary diamond-shaped anastomosis (**d**, **e**)

circumference (HC) recorded on the P50 centile growth charts. The patient tolerates full oral feeding very well.

Discussion

Intestinal atresia is a frequent cause of neonatal intestinal obstruction and requires emergent surgical correction. Newborns with this congenital malformation often present with bilious vomiting and abdominal distension. The anatomical atresia lesion location is itself considered a key important factor for the surgeon to carefully consider as we know this may substantially increase operative morbidity [5]. In high jejunal atresia lesions the surgeon is faced with challenges [6]. Yamataka et al. [4] first proposed deployment of a bilateral side plication(s) technique for successful correction of high jejunal atresia while others have favored first undertaking an enterostomy (i.e., double barrel, Santulli, or Bishop-Koop ostomy(s)) to offset risks of anastomotic disruption and leakage [7]. De Carli et al. [5] reported a complicated high jejunal atresia index case in which successful management was eventually undertaken with T-tube enterostomy. Every jejunal atresia encountered with its variant classification subtypes thus presents distinct challenges where the surgeon must be creative to achieve a successful outcome.

Ken Kimura (1977) first described the diamond-shaped duodeno-duodenal anastomosis for operative repair of congenital duodenal atresia [8]. This technique offers many practical theoretical advantages by providing in principle 'a more physiologic intestinal anastomosis' leading to the early recovery of gut function and appreciably a lower incidence (%) of blind loop syndrome [9].

By performing a Kimura jejunojejunostomy in this particular challenging index case we herein report gut function recovered quickly within a week after operation and no trans-anastomotic feeding tube (TAT) was needed.

Conclusion

We wish to highlight and recommend the Kimura operation as a versatile operative procedure for the definitive management of congenital high jejunal atresia(s). It offers many practical advantages and can be undertaken safely with minimal complication(s).

Abbreviations

DJ	Duodenojejunal
DJFX	DJ flexure
JIA	Jejunoileal atresia
TPN	Total parenteral nutrition
AXR	Abdominal x-ray film

Acknowledgements

We thank Dr. Pitthawat Julnipithawong and Dr. Pawara Yuktawet our Pediatric Surgery Residents at Ramathibodi Hospital Mahidol University for assisting with the index case and aftercare follow-up.

Authors' contributions

AB — author and corresponding author. PDL — drafting, editing, co-author, and final manuscript approval.

Funding

Not applicable.

Availability of data and materials

Data supporting the result of this case report can be found in our hospital database.

Declarations

Ethics approval and consen to participate

This study was approved by Institutional Review Boards in Mahidol University COA. MURA2022/458

Consent for publication

All presentations of case reports have consent to published signed.

Competing interests

The authors declare that they have no competing interests.

Received: 15 December 2022 Accepted: 28 July 2023
Published online: 14 August 2023

References

1. Stollman TH, de Blaauw I, Wijnen MHWA, van der Staak FHJM, Rieu PNMA, Draaisma JMT, et al. Decreased mortality but increased morbidity in neonates with jejunoileal atresia; a study of 114 cases over a 34-year period. J Pediatr Surg. 2009;44(1):217–21. https://doi.org/10.1016/j.jpedsurg.2008.10.043.
2. Marei MM, Abouelfadl MH, Rawwash AAE, Seleim HM, Mahmoud WM, Yassin TYM, et al. Early outcomes of tapering jejunoplasty by antimesenteric seromuscular stripping and mucosal inversion for proximal jejunal atresia. Egypt Pediatr Assoc Gazette. 2019;67(1):4. https://doi.org/10.1186/s43054-019-0003-9.
3. Kumaran N, Shankar KR, Lloyd DA, Losty PD. Trends in the management and outcome of jejuno-ileal atresia. Eur J Pediatr Surg. 2002;12(3):163–7. https://doi.org/10.1055/s-2002-32726.
4. Yamataka A, Koga H, Shimotakahara A, Kobayashi H, Lane GJ, Miyano T. Novel procedures for enhancing high jejunal atresia repair: bilateral side-plication and plication before anastomosis. Pediatr Surg Int. 2005;21(11):907–10. https://doi.org/10.1007/s00383-005-1509-3.
5. De Carli C, Ojeda M, Veloce D, González M. T-tube enterostomy for the management of complicated high jejunal atresia. An innovative procedure for a complex intestinal entity. A technical report. J Pediatr Surg Case Rep. 2016;7:39–42. https://doi.org/10.1016/j.epsc.2016.02.016.
6. Tongsin A, Anuntkosol M, Niramis R. Atresia of the jejunum and ileum: what is the difference ? J Med Assoc Thai. 2008;91(Suppl 3):S85-9.
7. Eeftinck Schattenkerk LD, Backes M, de Jonge WJ, van Heurn ELW, Derikx JPM. Treatment of Jejunoileal Atresia by primary anastomosis or enterostomy: double the operations, double the risk of complications J Pediatr Surg. 2021 https://doi.org/10.1016/j.jpedsurg.2021.07.021.
8. Kimura K, Tsugawa C, Ogawa K, Matsumoto Y, Yamamoto T, Asada S. Diamond-shaped anastomosis for congenital duodenal obstruction. Arch Surg. 1977;112(10):1262–3. https://doi.org/10.1001/archsurg.1977.01370100116026.
9. Kimura K, Mukohara N, Nishijima E, Muraji T, Tsugawa C, Matsumoto Y. Diamond-shaped anastomosis for duodenal atresia: an experience with 44 patients over 15 years. J Pediatr Surg. 1990;25(9):977–9.

Publisher's Note