

ORIGINAL RESEARCH

Open Access



Ultrasonography in diagnosis of appendicitis and its complications in pediatric patients: a cross-sectional study

Parisa Hajalioghli¹, Soroush Mostafavi^{2,3} and Mohammad Mirza-Aghazadeh-Attari^{3,4*}

Abstract

Background: Appendicitis is a common cause of acute abdomen in pediatrics. Although various criteria have been suggested in early diagnosis of appendicitis, these criteria are not as applicable for pediatric patients. Because of this, imaging has an important role in the diagnosis of appendicitis in pediatric patients. The present study was conducted on 121 pediatric patients with possible diagnosis of appendicitis. All of the patients underwent initial evaluation and then underwent sonographic imaging. Sonography was used to assess the existence of signs associated with appendicitis, or its complications. Imaging findings were compared in patients with complications with those with complications. True false positive, false negative, true positive, and true negative values were calculated. Sensitivity and specificity of ultrasonography in determining appendicitis was evaluated.

Results: The mean age of children was 8.08 ± 3.25 years, with ages ranging from 3 to 14 years. Of the 121 children, 74(61.2%) were male and 47(38.8%) were female. In total, there were 3(2.4%) false positives and 2(1.6%) false negatives based on sonographic findings. There were also 54(44.6%) true positive and 62(51.2%) true negative based on sonographic findings. Based on the findings of ultrasound in this study, ultrasound sensitivity was 96.4%, specificity was 95.3%, positive predictive value was 94.7%, and negative predictive value was 96.8%.

Conclusion: Ultrasonography is indicated in the diagnosis of appendicitis in pediatric patients and has optimal sensitivity and specificity in the diagnosis. Furthermore, it is a suitable diagnostic method for evaluating complications of appendicitis.

Keywords: Appendicitis, Pediatrics, Abdomen, Sonography, Diagnostics

Background

Appendicitis is one of the common causes of acute abdomen in pediatric patients [1]. Although the pathophysiological characteristics of appendicitis are well understood and clear, the same cannot be said about its clinical signs and symptoms and diagnosis. Because of the obscure nature of disease progression and existence of multiple differential diagnosis which exactly mimic its clinical findings, scholars have suggested clinical criteria

for the detection and management of appendicitis [2]. One of the most recognized of these criteria is the Alvarado scale and the modified Alvarado scale, where patients are classified to low-, intermediate-, and high-risk patients. Although this criterion is shown to be a powerful tool in the proper diagnosis of appendicitis, it partly depends on subjective information from the patients [3]. This is particularly problematic in pediatric patients, because of the inability of the patient to properly express some of the criteria mentioned in the scoring system. Practical evidence approves this statement, as studies performed on pediatric patients have generally regarded the Alvarado score to be less specific in pediatric patients compared to adults. More so, this scale

* Correspondence: m.aghazadeh75@yahoo.com

³Aging Research Institute, Tabriz University of Medical Sciences, Tabriz, Iran

⁴Medical Radiation Sciences Research center, Tabriz University of Medical Sciences, Tabriz, Iran

Full list of author information is available at the end of the article

is shown to better rule out patients rather than rule them in [4].

All of the aforementioned issues have mediated the increasing use of biomedical imaging methods in the diagnosis of appendicitis, such as CT scan and ultrasonography [5, 6]. Ultrasonography is currently being considered as the first line of diagnostic imaging because of its ease of performance and relatively low cost, but limitations remain regarding its sensitivity and specificity in diagnosing appendicitis. Furthermore, some studies have suggested that this technique does not significantly reduce the rate of negative appendectomy and should not be routinely considered in clinical decision making, while others have suggested otherwise [7]. Moreover, because of operator-dependent characteristic of ultrasonography, results could vary greatly in different clinical settings, where sonography is not performed by radiology specialists [8]. In this study, we examine the efficacy of ultrasonography in diagnosing appendicitis in pediatric patients.

Methods

Patients

The present descriptive analytical study was performed in the pediatric referral center of north east of Iran. Of all of the patients being referred to the hospital with the possible diagnosis of acute appendicitis, 121 subjects were included. Inclusion criteria consisted of being between 2 and 15 years old, existence of abdominal pain, pain in the right iliac fossa or right lower quadrant and being in a stable hemodynamic condition. Exclusion criteria consisted of being in a state of shock.

Sonographic evaluation

All of the subjects were first evaluated by a pediatric surgeon with more than 10 years of experience. Those with suspected appendicitis were then referred to the radiology ward to undergo sonographic evaluation, which was done by Sonix-OP, utilizing a linear probe (5–14 MHz), and a convex probe (5–9 MHz). Patients were then classified to three groups: group 1 where does with normal findings (appendix diameter equal or less than 6 mm and compressible appendix). These patients underwent further evaluation for right lower quadrant pain. The second group were those with findings which strongly suggested appendicitis (diameter of the appendix more than 6 mm, non-compressible appendix). These patients underwent further ultrasonographic evaluation for existence of complications of acute appendicitis, such as abscess formation, free fluid in the abdomen, hyper-echo line under the mucosa, and increased echogenicity of fatty tissue surrounding the appendix. The third group were patients in which the appendix was not visualized. These patients were further classified

to two subgroups, those with findings suggestive of another etiology for pain, and those with findings suggestive for acute appendicitis, such as free abdominal fluid, localized dilation of small intestine loops, and inflammation in the fatty tissue surrounding the appendix.

Follow-up of patients

Patients underwent appendectomy based on the most recent guidelines. Pathologic results were then compared with imaging findings.

Patients which did not undergo surgery were followed for one week after their discharge from the hospital. A second follow-up session was done 1 month after discharge.

Statistical analysis

Analysis was done by SPSS version 18. Normality was assessed by Kolmogorov-Smirnov test. Chi-squared test was used for qualitative variables and independent *t* test was used for quantitative variables. Correlation between variables was assessed by Spearman test. *p* less than 0.05 was considered significant. The power of the study was set at 80%.

Ethical considerations

The present study was performed in a tertiary medical center. The study was performed by the local ethics board of this institution, and the university to which it was affiliated with. The imaging was done based on a previously established guideline in the center the study was performed. This study was performed based on guidelines of the Helsinki declaration.

Results

The mean age of children was 8.08 ± 3.25 years, with ages ranging from 3 to 14 years. Of the 121 children, 74(61.2%) were male and 47(38.8%) were female. The average age of boys was 8.16 ± 3.23 years and the average age of girls was 7.95 ± 3.30 years. The average age at admission was not significantly different between boys and girls ($p = 0.737$).

Concerning the symptoms of the disease, 166(95.9%) had abdominal pain, 67(55.4%) had nausea and vomiting, and 53(43.8%) had anorexia. On the abdominal examination, 102(84.3%) had RLQ tenderness, 21(17.4%) had rebound tenderness, and 15(12.4%) had guarding. According to the ultrasound findings, there were 37 cases (30.6%) of normal appendix) compressible with a diameter of less than 6 mm, 49 cases (40.5%) of inflamed appendix (uncompressible and less than 6 mm in diameter), and 35 cases (28.9%) of non-visible appendix.

The average diameter of appendix in the group, along with the normal appendix, was 4.53 ± 1.06 mm.

Table 1 Ultrasonography findings in patients with appendicitis

Observed radiological findings	Frequency
Mean appendix diameter	8.57±3.01
Appendicoliths	13 (26.5%)
Disruption of sub-mucosal membrane	16 (32.7%)
Free fluid	16 (32.7%)
Secondary signs	
Increased echogenicity In peri-appendicular fat	38 (77.6%)
Lymphadenopathy	7 (14.3%)
Fluid collection	12 (24.5%)
Local dilation of intestinal loops	5 (4.1%)

Frequency of ultrasound evidence and secondary signs in 49 patients with inflamed appendices in ultrasound were in accordance with Table 1.

Frequency of ultrasound evidence and secondary signs in 49 patients with inflamed appendices in ultrasound based on perforation or non-perforation, as shown in Table 2.

The frequency of secondary signs in 35 patients with non-visualized appendices in ultrasound is in accordance with Table 3.

Secondary signs were seen in 8(22.9%) patients out of 35 patients with non-visualized appendices in ultrasound, 7(20.0%) of whom had perforated appendicitis, and 1(2.9%) had non-perforated appendicitis.

Table 4 shows the frequency of clinical and laboratory findings based on appendix ultrasonography.

Of the 121 patients, 62 patients (51.2%) did not undergo surgery and were monitored. Two cases from group 2 with improvement of symptoms, 33 cases from group 1, and 27 cases from group 3 with no secondary signs.

Fifty-nine patients underwent surgery. Forty-seven patients from group 2, 8 patients from group 3 with secondary signs, and 4 patients from group 1. Thirty-six patients had acute inflammatory appendicitis (29.8%), 21 patients (17.4%) had perforated appendicitis, and 2 patients (1.7%) had normal appendices.

Table 5 shows the frequency of diagnoses during surgery based on ultrasound findings.

Among the 59 patients who underwent surgery, the pathologic results were evaluated as confirmatory of the final diagnosis. Of the 47 patients in group 2 who underwent surgery, 46 had a positive pathology for appendicitis and 1 patient had normal appendix who was diagnosed with Meckel's diverticulum at surgery. Of the 8 patients in group 3 who underwent surgery, all had a positive pathology for appendicitis. Of the 4 patients in group 1 who underwent surgery, 2 had positive pathologic findings of appendicitis, 1 had bowel obstruction and one had complicated urachal cysts. According to this report, 40 cases (67.8%) of acute purulent appendicitis, 16 cases (27.1%) of gangrenous appendicitis, 1 case (0.8%) of urachal cyst and granulation tissue, and 1 case (0.8%) of normal appendix were reported.

In two patients, the appendicitis was ruled out during the subsequent flow-up due to the absence of secondary signs in the sonography, despite the high diameter of the appendix (more than 6 mm). Appendicitis was also suggested in three patients, despite the low diameter of appendix (less than 6 mm), due to secondary signs (disruption of sub mucosa) in sono which were also confirmed by pathological specimen results.

Of the 59 patients who underwent surgery, only 1 had a normal pathologic report, so a negative appendectomy rate was 1.7%.

Table 2 Ultrasonography findings in patients with appendicitis in regards to perforation status of the appendix

Observed radiological findings	With perforation	Without perforation
Mean appendix diameter		
Appendicoliths	8 (42.1%)	5 (16.7%)
Disruption of sub-mucosal membrane	11 (57.9%)	5 (16.7%)
Free fluid	7 (36.8%)	9 (30.0%)
Secondary signs		
Increased echogenicity In peri-appendicular fat	12 (63.2)	26 (86.7%)
Lymphadenopathy	4 (21.1%)	3 (10.0%)
Fluid collection	11 (57.9%)	1 (3.3%)
Local dilation of intestinal loops	3 (15.8%)	2 (6.7%)

Table 3 Frequency of secondary signs in patients with un-observable appendicitis

Secondary signs	Frequency
No secondary signs observed	27 (77.7%)
Secondary signs observed	
Increased peri-appendicular fat echogenicity	8(100%)
Lymphadenopathy	1(12.5%)
Local collection	5(62.5%)
Local dilation of intestinal loops	4(50%)

The following ultrasound diagnoses were made for the 33 patients in group 1 who did not undergo surgery: 14 cases with mesenteric lymphadenitis, 2 cases with intestinal invagination, 6 cases with terminal ileitis, 1 case with cystitis, and 10 cases with no signs of any disease.

The following ultrasound diagnoses were made for 27 patients in group 3 with secondary signs: 11 cases with mesenteric lymphadenitis, 2 cases with ureteral stones, and 14 cases with no signs of any disease.

In total, there were 3 (2.4%) false positives and 2 (1.6%) false negatives based on sonographic findings. There were also 54 (44.6%) true positive and 62 (51.2%) true negative based on sonographic findings.

Based on the findings of ultrasound in this study, ultrasound sensitivity was 96.4%, specificity was 95.3%, positive predictive value was 94.7%, and negative predictive value was 96.8%.

Figures 1, 2, and 3 illustrate imaging findings of selected patients. Figure 1 shows a blind loop with AP diameter of 7 mm at lower quadrant right mucosal layer in in favor of perforation with adjacent fluid collection (2.3 cc) and disruption of the mucosa of the appendix.

Figure 2 shows a non-compressible blind loop with A-P diameter more than 6 mm and target shape at its transverse view with adjacent hyper echogenicity of peripheral fat and luminal distention is noted which showed increased blood flow around the blind loop in color Doppler study in favor of appendicitis.

Table 4 Clinical signs and symptoms in patients being studied, in regards to ultrasonographic findings

Signs and symptoms	Normal appendicitis	Inflamed appendix	Non-visible appendix	<i>p</i> value
Abdominal pain	35 (94.6%)	48 (98%)	33 (94.3%)	0.633
Loss of appetite	12 (32.4%)	24 (49%)	17 (48.6%)	0.247
Nausea	19 (51.4%)	29 (59.2%)	19 (54.3%)	0.761
Tenderness	28 (75.7%)	45 (91.8%)	29 (82.9%)	0.120
Rebound tenderness	1 (2.7%)	11 (22.4%)	9 (25.7%)	0.017
Abdominal guarding	1 (2.7%)	6 (12.2%)	8 (22.9%)	0.035
Mean WBC count	10855.2± 3591.7	16533.2± 5112.0	13339.4± 4613.2	0.355

Figure 3 shows a non-compressible loop with a diameter of 9.55 mm. Axial view shows a typical case of target sign, characterized by a hypo-echo center, representing the existing intra-luminal fluid, and hyper echo rims representing the mucosa.

Discussion

Although appendicitis is common at all ages, it is one of the most common causes of acute abdominal pain in children and adolescents [9]. Various factors such as age, sex, race, geographical location, diet, and appendix position can affect appendicitis-related mortality [10]. The most important symptoms of appendicitis are abdominal pain, nausea, vomiting, and fever. Pain is the most common symptom and occurs in 50 to 100% of cases. Nausea and vomiting are usually followed by pain [11].

The pain is usually somatic and is felt around the umbilical region. In abdominal examination, in addition to tenderness and guarding, rebound tenderness is of great importance in diagnosis [12].

Proper and early diagnosis of appendicitis is important to reduce the complications of perforation. However, negative appendectomy often results in surgical and anesthetic complications such as positive appendectomy. Therefore, many methods have been suggested to improve diagnostic accuracy in suspicious cases, such as laboratory tests, ultrasound, CT, and laparoscopy. Among imaging modalities, ultrasound is a non-invasive, safe, inexpensive, and affordable method [13–17], more so, theoretically, Ultrasound has a higher diagnostic value, especially in children, because of their lower body thickness and less fat than adults [18, 19].

Sonographic findings in the diagnosis of acute appendicitis are divided into three groups: negative, positive, and suspicious. By evaluating secondary signs of acute

Table 5 Surgical findings in regard to ultrasonographic findings

	Normal appendix	Inflamed appendix	Non-visible appendix
	37	49	35
Normal	2 (5.4%)	0	0
Appendicitis	2 (5.4%)	31 (63.3%)	3 (8.6%)
Perforated appendix	0	16 (32.7%)	5 (14.3%)

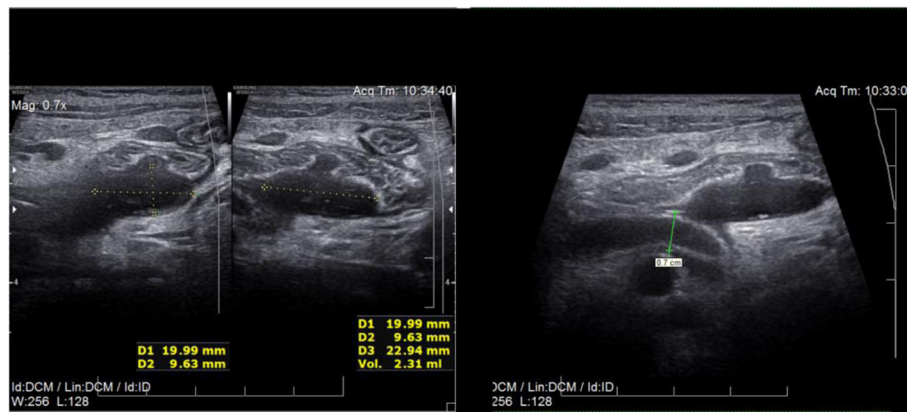


Fig. 1 Blind loop with AP diameter of 7 mm at lower quadrant right mucosal layer in in favor of perforation with adjacent fluid collection (2.3 cc) and disruption of the mucosa of the appendix

appendicitis in the absence of normal or inflamed appendicitis, it is possible to divide the suspicious group into positive and negative groups in terms of the probability of acute appendicitis [20].

In this regard, the use of ultrasound with a specially designed protocol for the diagnosis of acute and complicated appendicitis in children is necessary to increase the diagnostic accuracy.

As mentioned previously, ultrasound as a diagnostic modality in acute appendicitis depends on the operator and protocol, and because of this, it is necessary to determine sensitivity and specificity in each center [18].

Angelina et al., investigated the accuracy of sonography in the diagnosis of acute appendicitis in children. In this study, 317 children were referred to a tertiary pediatric hospital with acute abdominal pain. The results of this study showed that the positive predictive value of ultrasound was 92% and negative predictive value was 88%. Sensitivity and specificity were not calculated

because there were 43 patients with equivocal ultrasound results [9]. The results of our study are consistent with this study, with the difference that our study had a higher predictive value. The result could be because of the imaging protocol used in our study, where suspicious patients were further evaluated for signs of appendicitis.

In a retrospective study by Ross et al. on 968 children, the efficacy of ultrasonography in determining acute appendicitis in patients with non-visible appendix was studied. In 526 cases, the appendix was not found in sonography, of which 15.6% had a positive pathology for acute appendicitis. The sensitivity and specificity of ultrasound in the group where the appendix was fully visible were reported 99.5% and 81.3%, respectively. The study eventually found that children with no reassuring clinical examinations following incompletely visualized appendices on US may benefit from further imaging modalities, to reduce the rate of negative appendectomy [21]. We also noticed an increase in sensitivity and

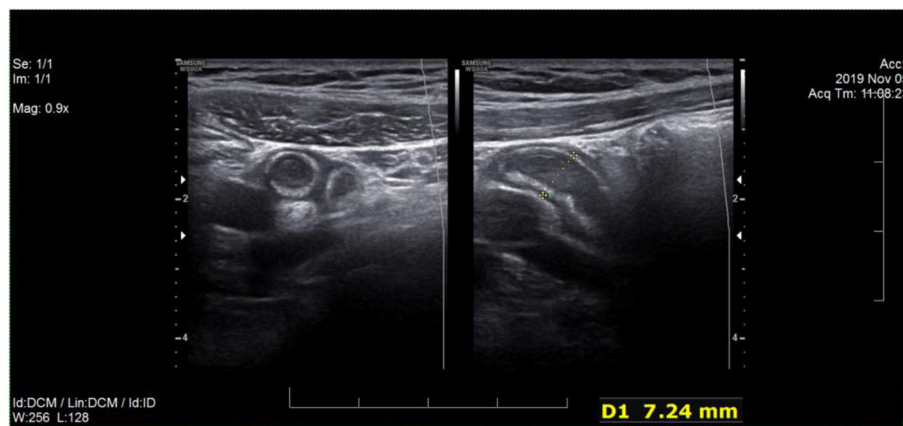


Fig. 2 Non-compressible blind loop with A-P diameter more than 6 mm and target shape at its transverse view with adjacent hyper echogenicity of peripheral fat and luminal distention is noted which showed increased blood flow around the blind loop in color Doppler study in favor of appendicitis

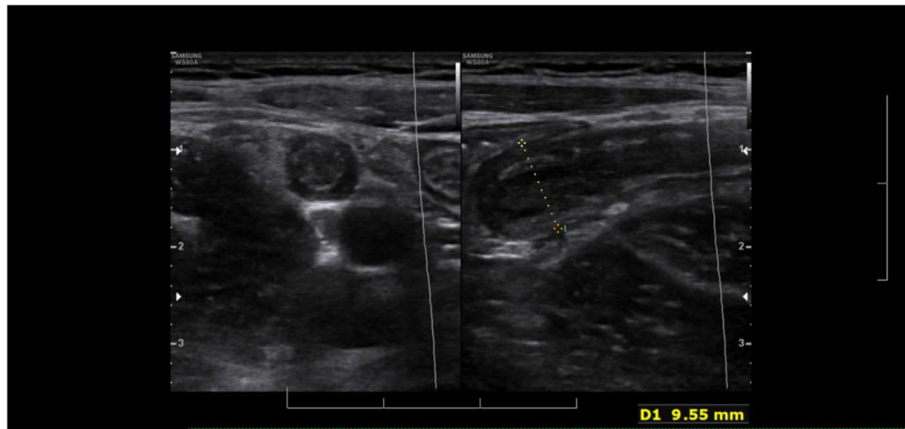


Fig. 3 Non-compressible loop with a diameter of 9.55 mm. Axial view shows a typical case of target sign, characterized by a hypo-echo center, representing the existing intra-luminal fluid, and hyper echo rims representing the mucosa

specificity following secondary evaluation. We utilized ultrasonographic evaluation, but CT scan can also be utilized, as mentioned previously. Interestingly Reddan et al claimed that up to 46% of ultrasound studies do not visualize the appendix and getting help with secondary signs in ultrasound can help make diagnosis more accurate [22].

Secondary evaluation could also assist in the early diagnosis of appendix perforation and secondary complications, such as abscess formation. Cuillin et al. concluded that ultrasonography could be effective in the diagnosis of perforated appendicitis and the best predictor for perforation was the absence of the echogenic sub-mucosal layer and presence of loculated fluid collection in the pelvis [23].

In the present study, fluid collection and sub-mucosal disruption were the most common findings of US in patients with perforated appendicitis. Importantly, in our study, perforation rate in the second group was 32.6%, and in the third group with secondary signs was 62.5%. This may indicate that perforation of the appendix is probably one of the causes of non-visualized appendix in sonography. It could also indicate that non-visualized appendix may be underdiagnosed, leading to perforation.

Regarding negative appendectomy, a study by Paydar et al showed that 79.5% of appendectomies had some degree of inflammation in the pathology report. Also, the rate of negative appendectomy was 20.5% [24].

However, in the present study, the rate of negative appendectomy was 1.7%, which may be due to differences in the criteria for selection of patients, as well as the main purpose of the study and how to evaluate patients.

In a study by Fraukje et al., of the 75 children who underwent appendectomy, 5% had a negative appendectomy. This difference in comparison with the present study may be due to a pathologist error or a reduction

in the rate of negative appendectomy based on this protocol [20].

Conclusion

In conclusion, it is necessary to reduce the complications of appendicitis perforation and minimize the number of negative appendectomies. This can be done by getting a detailed history, a thorough examination as well as diagnostic aids such as ultrasound. Based on the present study, ultrasound with the above mentioned protocol is an appropriate diagnostic method in the evaluation of appendicitis in children. In cases of non-visualized appendices, acute appendicitis can be ruled out with high confidence in the absence of secondary signs.

Abbreviations

CT: Computed tomography

Acknowledgements

We would like to thank the radiology staff of the medical educational center in which the case underwent diagnostic imaging. We would like to thank Dr. Armin Zarrintan for his efforts in the completion of the study.

Consent of publication

Oral and written consent was taken from the patient and one of the legal representatives (in this case, a family member)

Authors' contributions

PH: patient selection, interpretation of imaging, study conception, read and approved the final version. SM: Systemic review of literature, statistical analysis, patient selection, read and approved the final version. MMAA: Manuscript preparation, final edit, interpretation of imaging results, read and approved the final version. All authors have read and approved the manuscript.

Funding

This study did not receive any funding, other than that of provided by Tabriz University of Medical Sciences.

Availability of data and materials

All data and materials are available based on reasonable request, according to the guidelines of the institution in which the study was approved and

based on the guidelines regarding sharing patient information. Available upon request.

Ethics approval and consent to participate

The study was approved by the ethical board of the medical-educational center in which it was performed (number 1393-10-1/14). The patients being included had signed written informed consent note. Furthermore, all patients are informed that they may be subjects of scientific experiments, and their rights in this regard.

Competing interests

The authors declare no competing interests.

Author details

¹Department of Diagnostic Imaging, Faculty of Medicine, Tabriz University of Medical Sciences, Tabriz, Iran. ²Pediatric health Research center, Tabriz University of Medical Sciences, Tabriz, Iran. ³Aging Research Institute, Tabriz University of Medical Sciences, Tabriz, Iran. ⁴Medical Radiation Sciences Research center, Tabriz University of Medical Sciences, Tabriz, Iran.

Received: 15 January 2020 Accepted: 1 April 2020

Published online: 29 April 2020

References

1. Kwon JH, Koh SJ, Kim W, Jung YJ, Kim JW, Kim BG, et al. Mortality associated with proton pump inhibitors in cirrhotic patients with spontaneous bacterial peritonitis. *J Gastroenterol Hepatol*. 2014;29(4):775–81.
2. Becker C, Kharbanda A. Acute appendicitis in pediatric patients: an evidence-based review. *Pediatric emergency medicine practice*. 2019;16(9):1–20.
3. Mán E, Simonka Z, Varga Á, Rárosi F, Lázár G. Impact of the Alvarado score on the diagnosis of acute appendicitis: comparing clinical judgment, Alvarado score, and a new modified score in suspected appendicitis: a prospective, randomized clinical trial. *Surg Endosc*. 2014;28(8):2398–405.
4. White N, Crawford K. How accurate is the Alvarado scoring system in the diagnosis of acute appendicitis in adults and children? *Evidence-Based Practice*. 2016;19(11):E2–3.
5. Mostbeck G, Adam EJ, Nielsen MB, Claudon M, Clevert D, Nicolau C, et al. How to diagnose acute appendicitis: ultrasound first. *Insights into imaging*. 2016;7(2):255–63.
6. Vaghela K, Shah B. Diagnosis of Acute Appendicitis Using Clinical Alvarado Scoring System and Computed Tomography (CT) Criteria in Patients Attending Gujarat Adani Institute of Medical Science—A Retrospective Study. *Pol J Radiol*. 2017;82:726.
7. Löfvenberg F, Salö M. Ultrasound for appendicitis: performance and integration with clinical parameters. *Biomed Res Int*. 2016;2016.
8. Fujii Y, Hata J, Futagami K, Hamada T, Mitsuoka H, Teramen K, et al. Ultrasonography improves diagnostic accuracy of acute appendicitis and provides cost savings to hospitals in Japan. *J Ultrasound Med*. 2000;19(6):409–14.
9. ANG A, Chong NK, DANEMAN A. Pediatric appendicitis in "real-time": the value of sonography in diagnosis and treatment. *Pediatr Emerg Care*. 2001;17(5):334–40.
10. Humes D, Simpson J. Acute appendicitis. *Bmj*. 2006;333(7567):530–4.
11. Zarandi NP, Parsijani PJ, Bolandparvaz S, Paydar S, Abbasi H. Accuracy of Surgeon's Intraoperation Diagnosis of Acute Appendicitis, Compared with the Histopathology Results. *Bulletin of Emergency & Trauma*. 2014;2(1):15.
12. Snyder W. *Pediatric surgery*. Chicago. 1962.
13. Irish MS, Pearl RH, Caty MG, Glick PL. The approach to common abdominal diagnoses in infants and children. *Pediatr Clin N Am*. 1998;45(4):729–72.
14. Wagner JM, McKinney WP, Carpenter JL. Does this patient have appendicitis? *Jama*. 1996;276(19):1589–94.
15. Denjalic A, Delic J, Delic-Custendil S, Muminagic S. Variations in position and place of formation of appendix vermiformis found in the course of open appendectomy. *Medical Archives*. 2009;63(2):100.
16. Kumar S. Right-sided low inguinal pain in young women. *J R Coll Surg Edinb*. 1996;41(2):93–4.
17. Rosengren D, Brown AF, Chu K. Radiological imaging to improve the emergency department diagnosis of acute appendicitis. *Emerg Med*. 2004;16(5-6):410–6.
18. Mohammadi A, Khodabakhsh F. Sensitivity and specificity of ultrasonography in diagnosis of acute appendicitis. *Journal of Babol University of Medical Sciences*. 2009;11(3):42–7.
19. Quigley AJ, Stafrace S. Ultrasound assessment of acute appendicitis in paediatric patients: methodology and pictorial overview of findings seen. *Insights into imaging*. 2013;4(6):741–51.
20. Wiersma F, Toorenvliet BR, Bloem JL, Allema JH, Holscher HC. US examination of the appendix in children with suspected appendicitis: the additional value of secondary signs. *Eur Radiol*. 2009;19(2):455–61.
21. Ross MJ, Liu H, Netherton SJ, Eccles R, Chen PW, Boag G, et al. Outcomes of children with suspected appendicitis and incompletely visualized appendix on ultrasound. *Acad Emerg Med*. 2014;21(5):538–42.
22. Reddan T, Corness J, Mengersen K, Harden F. Ultrasound of paediatric appendicitis and its secondary sonographic signs: providing a more meaningful finding. *Journal of medical radiation sciences*. 2016;63(1):59–66.
23. Quillin S, Siegel MJ, Coffin CM. Acute appendicitis in children: value of sonography in detecting perforation. *AJR Am J Roentgenol*. 1992;159(6):1265–8.
24. Parsijani PJ, Zarandi NP, Paydar S, Abbasi HR, Bolandparvaz S. Accuracy of ultrasonography in diagnosing acute appendicitis. *Bulletin of Emergency & Trauma*. 2013;1(4):158.

Publisher's Note

Springer Nature remains neutral with regard to jurisdictional claims in published maps and institutional affiliations.

Submit your manuscript to a SpringerOpen[®] journal and benefit from:

- Convenient online submission
- Rigorous peer review
- Open access: articles freely available online
- High visibility within the field
- Retaining the copyright to your article

Submit your next manuscript at ► [springeropen.com](https://www.springeropen.com)